

Case Report

Lingual Mucosal Ulceration with Bony Sequestration

Ahmad Dzulfikar Samsudin¹ and Azmiza Syawani Jasni²

¹Department of Oral, Pathology & Maxillofacial Surgery, Faculty of Dentistry, Universiti Sains Islam Malaysia, Persiaran MPAJ, Jalan Pandan Utama, 55100, Kuala Lumpur, Malaysia.

²Department of Microbiology, Faculty of Medicine & Health Science, Universiti Putra Malaysia, 3400 UPM Serdang, Selangor, Malaysia.

Correspondence should be addressed to:

Ahmad Dzulfikar Samsudin; drads0521@usim.edu.my

Article Info

Article history:

Received: 28 April 2022

Accepted: 3 August 2022

Published: 1 September 2022

Academic Editor:

Azlina Mokhtar

Malaysian Journal of Science,
Health & Technology

MJoSHT2022, Volume 8, Special Issue
eISSN: 2601-0003

<https://doi.org/10.33102/2022275>

Copyright © 2022 Ahmad Dzulfikar
Samsudin and Azmiza Syawani Jasni.

This is an open access article
distributed under the Creative
Commons Attribution 4.0 International
License, which permits unrestricted
use, distribution, and reproduction in
any medium, provided the original
work is properly cited.

Abstract — This case report describes a rare condition of lingual mucosal ulceration associated with bony sequestration following non-surgical lower molar tooth extraction of a healthy 58-year-old female patient. Clinically, she presented with a painful ulcer on the lingual aspect of the posterior mandible and noticed a sharp bone which caused irritation to the side of the tongue. The exposed bone was removed surgically, and the ulcer was completely healed. Thus, emphasizing the understanding of the causative factors of oral ulcers can help in giving a proper treatment plan.

Keywords — Lingual Mucosal Ulceration; Bony Sequestration; Oral Ulceration; Bone Dehiscence

I. INTRODUCTION

Infection and alveolar osteitis are the two most common complication following a lower third molar extraction [1]. Other complications are soft tissue injuries, root fracture, bleeding, damage of the adjacent structures and paraesthesia due to nerve injury to the inferior alveolar or lingual nerves [2]. On the other hand, lingual mucosal ulceration (LMU) with bony exposure is a rare complication that can occur following lower wisdom tooth extraction.

The lower posterior teeth usually are lingually inclined, protecting the underlying mucosa. The loss of one or more lower molars allows masticatory pressures and occlusal damage, leading to trauma to the lingual mucosa. Additionally, the mucosa covering the mandible's lingual cortex is delicate particularly in the posterior supramylohyoid region. The prominence of the mylohyoid ridge, exostosis or mandibular tori puts this area at risk for traumatic ulceration and bone

denudation [3]. Due to the disruption and poor periosteal blood supply, the exposed lingual cortex is prone to ischemic necrosis and possible sequestration [4].

Although lingual mucosal ulceration with bony sequestration is uncommon in daily dental practice, oral maxillofacial surgeons are familiar with this condition, particularly in patients who have had a lower mandibular molar tooth extracted. Therefore, it is paramount for general dental practitioners to be familiar with the possible causes, differential diagnoses, and clinical presentations.

This case report will describe a rare case of lingual mucosal ulceration associated with bony sequestration following lower molar tooth extraction and its management.

II. CASE REPORT

A 58-year-old female was referred from private dental practice complaining of a painful ulcer associated with sharp bone at the lower left lingual mucosa (Fig. 1). The ulcer developed ten days after her lower left wisdom tooth was extracted. She claimed that the extraction was uncomplicated, and they faced no difficulty. The painful ulcer was also associated with an ulcer at the lateral border of the left tongue. The systematic medical review revealed neither she is suffering from any medical illnesses including radio chemotherapy nor taking any medication. She does not smoke or consume alcohol.

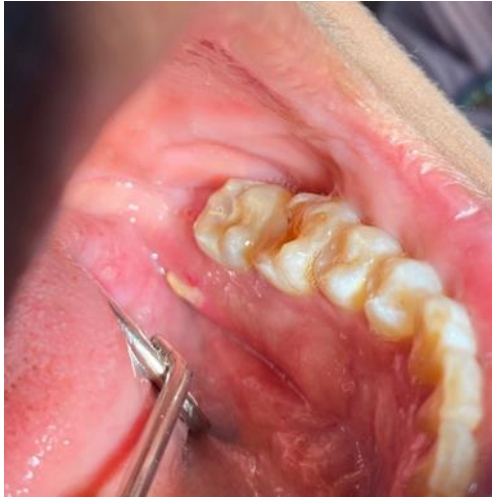

Fig. 1 Exposed bone at the lingual part of the mandible

Intraoral clinical examination revealed that the lower left third molar (38) was absent. The extraction wound socket was healing fine. There was an exposed mucosal ulceration and a tiny white cortical bone ledge, approximately 2mm x 5mm in length at the lingual to 38 region, above the mylohyoid ridge. It was sharp, rough, immobile, and tender to touch. The surrounding lingual mucosa appeared reddish (erythematous) and inflamed. No discharge or active bleeding was noted. An area of halo ulceration was also present at the lateral border of the adjacent tongue at the same level with the exposed bone. No extraoral abnormalities detected.

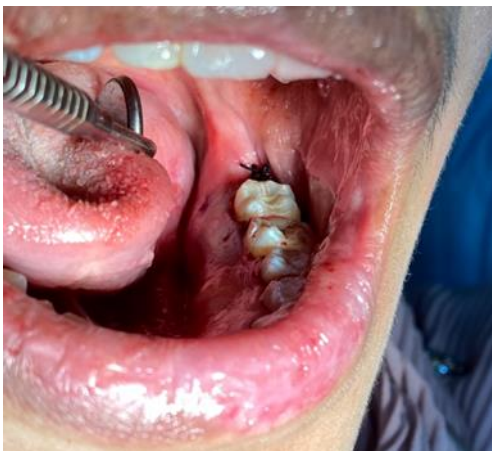

Fig. 2 Post-surgical removal of bone sequestration.

The sharp bony ledge was removed under local anaesthesia - inferior alveolar nerve, lingual nerve and long buccal nerve were blocked. The incision was made using blade #15 to create an envelope flap. The flap was raised gently using Molt #9 periosteal elevator. A small bone rongeur was used to remove sharp bone speckles and it was smoothed with bone files. The flap was sutured with non-resorbable black silk 4/0 suture (Fig. 2). No suturing was performed at the fenestrated lingual tissue. The patient was prescribed with Paracetamol tablets and Gengigel Oral Gel to be applied four times daily. Antibiotics were not prescribed. Postoperative instruction was given including maintenance of oral hygiene with the aid of antiseptic mouthwash (chlorhexidine gluconate 2%).

At one week's follow-up, the patient reported a considerable reduction in discomfort, and the presence of granulation tissue at the location of bone exposure was identified (Fig. 3). No additional therapy is necessary.

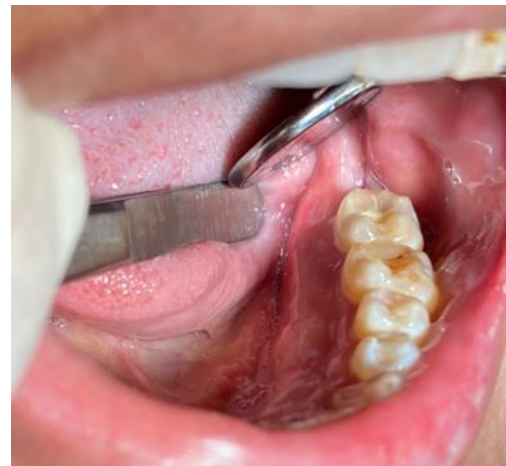

Fig. 3 Complete healing after 2 weeks post-surgery.

Dental panoramic tomography (DPT) showed no abnormalities detected as shown in Fig. 4. Cone beam computed tomography (CBCT) scan revealed the presence of tiny bony portion dissociated from the lingual cortical bone in the area of 38 (Fig. 5). There was no other significant finding noticed.

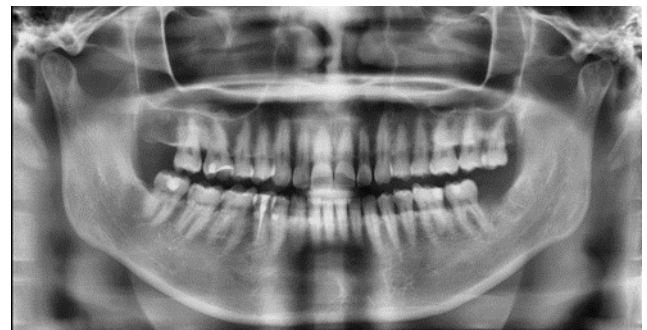

Fig. 4 Dental panoramic tomography (DPT) showed no significant findings at the area of 38.

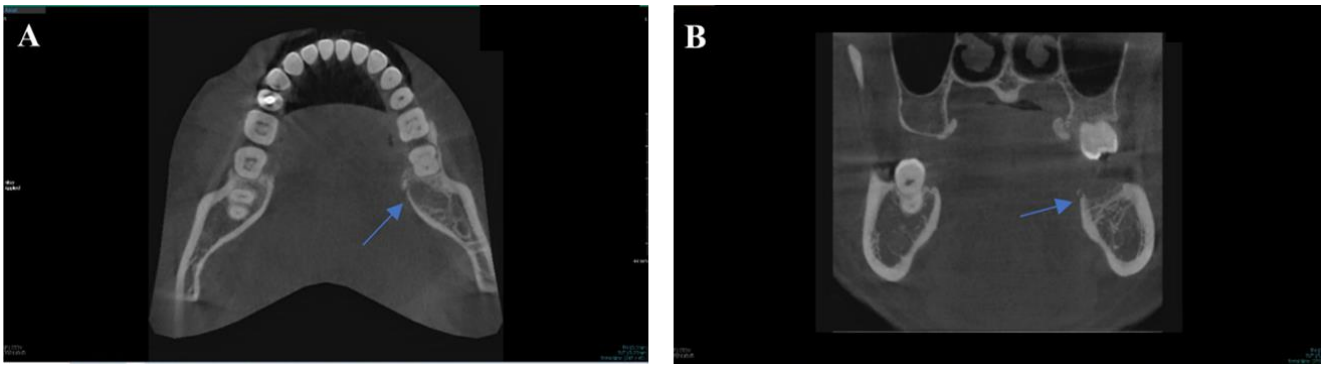


Fig. 5 Cone beam computed tomography (CBCT) showed bony sequestra. A-sagittal view, B-coronal view.

III. DISCUSSION

The incidence and prevalence of lingual mucosal ulceration with bony sequestration following lower third molar extraction in the general population are unknown and rarely reported in the literature [5, 6]. Although this condition is familiar among oral and maxillofacial surgery team, it can be clinical and therapeutic challenging for the general dental practitioner.

The causative factors can be local such as trauma, chronic odontogenic infections, self-inflicted or systemic factors including radiotherapy of head and neck cancer, bisphosphonate therapy, long-term corticosteroid usage and clotting disorders.

Prior to treatment, the local anatomy of the lingual medial shelves must be assessed. This is important to establish a proper treatment strategy. Referral to an oral maxillofacial surgery team is an option for management, particularly when the lesion does not respond to non-surgical intervention.

In the present case, we cannot confirm the exact etiology as the extraction was atraumatic and the patient's medical history was clear. However, the ulceration with bony sequestration following lower third molar extraction can be possibly caused by a fracture of the cortical plate, particularly on the lingual side of the socket, which is typically quite thin. The buccal-lingual movement that used to expand the tooth socket during tooth extraction may result in the fracture of the thin plate [7, 8].

Age can be another indicator of this mechanism of injury. In elderly patient, the bone became mature and decreased elasticity. This may result in an increased incidence of bone plate fractures during tooth extraction and caused injury to the mucosa [7].

While the associated symptoms are typically mild, they can last for several weeks as the sharp irregularity undergoes bone remodeling. To alleviate pain associated with swallowing or chewing, the bony irregularity may need to be removed or smoothed.

The treatment modalities can be conservative or surgical depending on whether the patient is symptomatic or asymptomatic. Conservative treatment includes the prescription of antiseptic mouthwash, antibiotics and anti-inflammatory creams which are helpful to aid the healing process [9]. A broad-spectrum antibiotic such as Amoxicillin 500 mg three times daily for five days can be prescribed to control acute phase of the condition. To reduce discomfort,

anti-inflammatory medications such as Mefenamic acid, Ibuprofen, and Diclofenac can be given. Topical hyaluronic acid (HA) such as Gengigel gel also can be applied three to five times daily to aid in tissue healing. HA is a natural glycosaminoglycan that helps in activation and moderating inflammatory response. It ensures optimal hydration of the oral mucosa and promotes faster healing times. Given sufficient time, the exposed bone may become loose by itself. Since this patient is symptomatic, removing a sharp bone is advisable. There are two surgical options. The first technique involves trimming the fragment through the existing mucosal perforation, while the second technique involves raising a mucoperiosteal flap and removing the bone speckles with a surgical bur or a bone file. [10]. In this case, the latter technique was chosen as an attempt to remove the bone through the perforation may result in a larger dehiscence in the mucosa and the exposure of more cortical bone [7, 10].

Similar to many other types of oral ulcers, ulcer of the tongue typically resolves on its own. Numerous researchers report that most lesions heal in 4-14 days without intervention.

IV. CONCLUSIONS

Lingual mucosal ulceration with bone sequestration is one of the post-extraction complications. Proper management which includes thorough debridement and removal of the sequestered bone would ensure optimal healing of this affected site. General dental practitioners must be familiar with the potential etiology and clinical presentation to rule out any alarming pathology.

CONSENT TO PARTICIPATE

Written informed consent was obtained from the patient for the anonymized information to be published in this article.

CONFLICT OF INTERESTS

The authors declared no conflict of interest and did not receive any funding for this article.

ACKNOWLEDGEMENT

We would like to thank the patient who consented to images that have been taken prior, during, and post-surgery for the purposes of this publication.

REFERENCES

- [1] Chen, Y. W., Chi, L. Y., & Lee, O. K. S. (2021). Revisit incidence of complications after impacted mandibular third molar extraction: A nationwide population-based cohort study. *PloS one*, 16(2), e0246625. doi.org/10.1371/journal.pone.0246625
- [2] Sayed, N., Bakathir, A., Pasha, M., & Al-Sudairy, S. (2019). Complications of Third Molar Extraction: A retrospective study from a tertiary healthcare centre in Oman. *Sultan Qaboos University Medical Journal*, 19(3), e230. doi.org/10.18295/squmj.2019.19.03.009
- [3] Tolstunov, L., Brickeen, M., Kamanin, V., Susarla, S. M., & Selvi, F. (2016). Is the angulation of mandibular third molars associated with the thickness of lingual bone?. *British Journal of Oral and Maxillofacial Surgery*, 54(8), 914-919. doi.org/10.1016/j.bjoms.2016.06.005
- [4] Rogers, S. N., Harvey-Woodworth, C. N., Hare, J., Leong, P., & Lowe, D. (2012). Patients' perception of the financial impact of head and neck cancer and the relationship to health related quality of life. *British Journal of Oral and Maxillofacial Surgery*, 50(5), 410-416. doi.org/10.1016/j.bjoms.2011.07.026
- [5] Juma Alkhabuli, B. D. S., MDentSci, M. F. D. S., Vladimir Kokovic, B. D. S., & Alkhabuli, J. (2015). Post extraction lingual mucosal ulceration with bone necrosis. doi.org/10.1016/j.sjdr.2015.04.002
- [6] Palla, B., Burian, E., Klecker, J. R., Fliefel, R., & Otto, S. (2016). Systematic review of oral ulceration with bone sequestration. *Journal of Cranio-Maxillofacial Surgery*, 44(3), 257-264. doi.org/10.1016/j.jcms.2015.11.014
- [7] Alves-Pereira, D., Figueiredo, R., Valmaseda-Castellón, E., Laskin, D. M., Berini-Aytés, L., & Gay-Escoda, C. (2013). Sharp mandibular bone irregularities after lower third molar extraction: Incidence, clinical features and risk factors. *Medicina Oral, Patologia Oral y Cirugia Bucal*, 18(3), e455. doi.org/10.4317/medoral.18700
- [8] Huang, C., Zhou, C., Xu, M., & Zou, D. (2020). Risk factors for lingual plate fracture during mandibular third molar extraction. *Clinical Oral Investigations*, 24(11), 4133-4142. doi.org/10.1007/s00784-020-03286-5
- [9] Goel, R. M., Ormond, M., Nayee, S., Hullah, E. A., Sanderson, J. D., & Escudier, M. (2015). A guide to oral ulceration for the medical physician. *British Journal of Hospital Medicine*, 76(6), 337-342. doi.org/10.12968/hmed.2015.76.6.337
- [10] Kharazmi, M., Carlsson, A. P., & Hallberg, P. (2014). Oral surgery: Prominent bone shelves. *British Dental Journal*, 216(10), 544-545. doi.org/10.1038/sj.bdj.2014.406