

Case Report

Acute Ischaemic Stroke in a COVID-19 Patient on Baricitinib - A Causal Effect or a Multifactorial Relationship?

Wei Ming Tan¹, Hana Maizuliana Solehan¹, Sarah Zulaikha Samad¹, M Firdaus A Bakar¹, Nor Safiqah Sharil¹, Nur Ezzaty Mohammad Kazmin¹, Fatimah Zanirah¹ and Koon Ket Sia²

¹Department of Medicine, Faculty of Medicine and Health Sciences, Universiti Sains Islam Malaysia (USIM), Persiaran Ilmu, Putra Nilai, 71800 Nilai, Negeri Sembilan, Malaysia.

²Department of Internal Medicine, Hospital Ampang, Jalan Mewah Utara, Taman Pandan Mewah, 68000 Ampang Jaya, Selangor, Malaysia.

Correspondence should be addressed to:

Wei Ming Tan; drtanweiming@usim.edu.my

Article Info

Article history:

Received: 24 April 2022

Accepted: 14 June 2022

Published: 1 September 2022

Academic Editor:

Sharifah Najwa Syed Mohamad

Malaysian Journal of Science,
Health & Technology

MJoSHT2022, Volume 8, Special Issue

eISSN: 2601-0003

<https://doi.org/10.33102/2022265>

Copyright © 2022 Wei Ming Tan et al.

This is an open access article distributed under the Creative Commons Attribution 4.0 International License, which permits unrestricted use, distribution, and reproduction in any medium, provided the original work is properly cited.

Abstract — Coronavirus disease 2019 (COVID-19), a multisystemic disorder caused by severe acute respiratory syndrome coronavirus 2 (SARS-CoV-2), has been associated with both venous and arterial thromboses. The hypercoagulable state of the disease poses a challenge to the patient's management. We herein report a case of acute ischaemic stroke in a COVID-19 patient who had been treated with three days of Baricitinib, an immunotherapy that can potentially augment the thrombotic risks. The case highlights the dilemma faced when initiating immunotherapy in a COVID-19 patient and emphasises the importance of evaluating the patient's thrombotic risks, balanced against the benefit of immunotherapy, to facilitate the selection of ideal candidates for the immunotherapy.

Keywords — Ischaemic Stroke; COVID-19; Arterial Thrombosis; Baricitinib

I. INTRODUCTION

Acute ischaemic stroke is not uncommon in patients with COVID-19. In a recent systematic review and meta-analysis by Luo et al., 2022, ischaemic stroke was found to be in almost 2% of patients with COVID-19 infection, albeit other studies have shown an overall stroke risk of as low as 0.5-0.9 % [1]. The wide variation in the stroke incidence rates in COVID-19 patients among different studies can be attributed to multiple factors, ranging from the difference in the population comorbidities to the discrepancy in methodologies.

On the other hand, various treatment strategies for COVID-19 infection, comprising steroids, antivirals and immunotherapy, have been used and tested with different efficacies. However, they do result in adverse effects if not being considered and used judiciously.

This case report describes the occurrence of an acute ischaemic stroke in a middle-aged, previously healthy COVID-19 patient with baricitinib being started as adjuvant therapy.

II. CASE REPORT

A 46-year-old gentleman with no previous medical illness or family history of cardiovascular disease presented to the emergency department with a 12-day history of fever and a 2-day history of shortness of breath. Besides being an electronic cigarette user for a few years, he was newly diagnosed with dyslipidaemia during the current admission. The rapid SARS-CoV-2 antigen detection test done at home using a salivary sample was positive, which was later confirmed by reverse transcription-polymerase chain reaction on the ward. On

presentation, his blood pressure was 125/76 mmHg with a heart rate of 95 beats per minute, a blood sugar of 8.4 mmol/L and a temperature of 36.8°C. However, he was tachypnoeic with a respiratory rate of 26 breaths per minute and oxygen saturation of 76% on room air. In view of type 1 respiratory failure on arterial blood gas, he was started on 15L/min oxygen via a non-rebreather mask. Physical examination was unremarkable except for fine bibasal crackles on lung auscultation. No atrial fibrillation was observed on the electrocardiogram.

Basic laboratory investigations revealed acute kidney injury with raised creatinine of 112 $\mu\text{mol/L}$ and liver transaminases (alanine transaminase of 215 U/L and aspartate transaminase of 164 U/L). Furthermore, the initial chest x-ray (CXR) demonstrated moderate bilateral pulmonary infiltrates with ground-glass opacity (Fig.1). In addition, reduced $\text{PaO}_2/\text{FiO}_2$ ratio of 115 mmHg, raised C-reactive protein (CRP) of 85 mg/L, lymphopenia of $0.7 \times 10^3/\mu\text{L}$, markedly elevated serum ferritin of 5847 $\mu\text{g/L}$, increased lactate dehydrogenase of 567 U/L and normal procalcitonin level, coupled with CXR findings and the clinical condition suggested that he was in the hyperinflammatory phase of COVID-19. Hence, a once-daily dose of 20 mg intravenous dexamethasone was commenced according to the standard local hospital protocol at the time of admission. Besides, the patient was also initiated on a treatment dose of subcutaneous fondaparinux to empirically treat for pulmonary embolism in view of raised D-dimer of 1.06 $\mu\text{g/ml}$ and S1Q3T3 electrocardiographic abnormality.

However, a further reduction of $\text{PaO}_2/\text{FiO}_2$ ratio to 82 mmHg on day 3 of hospitalisation prompted the addition of a once-daily dose of 4 mg oral baricitinib, a reversible Janus-associated kinase (JAK)-inhibitor, in view of the clinical condition of the patient not improving and serum ferritin remaining elevated at 5383 $\mu\text{g/L}$. High-resolution computed tomography (CT) and CT pulmonary angiography confirmed features of severe COVID-19 pneumonia with no evidence of pulmonary embolism or pulmonary angiopathy.

On day 6 of hospitalisation, he was found in the morning to have right hemiparesis with a reduced Glasgow Coma Scale score of 11(E4V2M5). However, the time of onset was uncertain. Pupils were equal and reactive bilaterally. Neurological examination demonstrated hypotonic right upper and lower limbs with 1/5 on a Medical Research Council muscle power scale and 22 points on a National Institutes of Health Stroke Scale. Plantar reflex was equivocal on the right foot, with clonus demonstrated. No obvious cranial nerve involvement was noted.

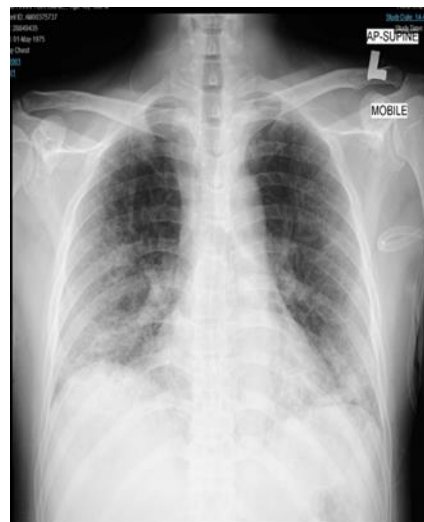

Fig.1 The initial chest radiography of the patient on admission.

An urgent CT scan of the brain did not show any significant abnormality (Fig.2). Thrombolytic service was not available at the respective hospital. A repeated CT scan of the brain on the next day revealed an acute left middle cerebral artery infarct with mass effect (Fig.3). Neurosurgical consultation was done, but the patient's family was not keen on the operation for fear of the anaesthetic and surgical complications. An echocardiogram demonstrated an ejection fraction of 60% with no vegetation or thrombus. Throughout the admission, his GCS remained constant, and oxygen was weaned off. He was later referred for rehabilitation at a specialised centre to aid in stroke recovery.

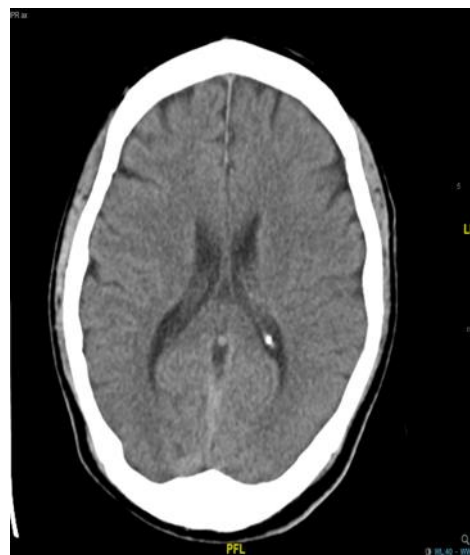


Fig.2 The urgent CT brain of the patient on day 6 of hospitalisation after the presence of right hemiparesis.

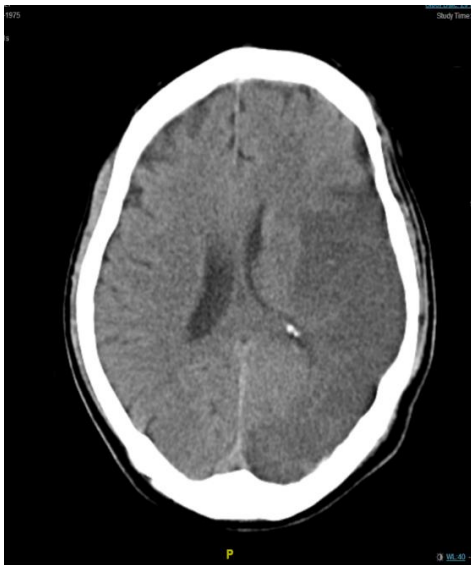

Fig.3 The repeated CT brain of the patient on day 7 of hospitalisation.

III. DISCUSSION

COVID-19 caused by SARS-CoV-2 is a multisystemic disorder involving not only the lungs but numerous vital organs in the human body. Both venous and arterial thromboses have been reported in patients infected with COVID-19 and have resulted in worse clinical outcomes and increased mortality [2]. The proposed mechanisms contributing to the hypercoagulable state of the disease comprise cytokine storm with augmented inflammatory markers like CRP from the hyperinflammatory process, activation of extrinsic coagulation pathway and platelet, and endothelial disruption [3, 4].

In addition, hypoxaemia experienced by our patient could contribute to the cerebrovascular event due to the imbalance between cerebral oxygen supply and demand. This resulted in cerebral infarction, especially in the presence of intracranial stenosis, as suggested by Nannoni et al., 2021 [4]. His thrombotic risk may have been further exacerbated by the presence of his newly diagnosed dyslipidaemia due to the association of dyslipidaemia with persistent platelet activation and the development of atherosclerosis [5]. A higher frequency of dyslipidaemia was also found, in addition to the other cardiovascular risk factors in COVID-19 patients who developed acute ischaemic stroke vis-à-vis those devoid of COVID-19 [6]. However, the answer to whether dyslipidaemia directly translates to a higher risk of ischaemic stroke in COVID-19 patients remains unclear. Besides, our patient's history of using electronic cigarette should not be overlooked. Albeit the relationship between electronic cigarettes and stroke was not established, endothelial dysfunction resulting from electronic cigarette usage may contribute to stroke [7].

The prothrombotic state of the disease, coupled with the complexity of our patient, poses a challenge to the treatment strategies. Medications, which are thought to halt the inflammatory cascades, may instead cause thrombotic complications. Thromboembolic events have been reported in patients receiving baricitinib, especially in those with advanced age and having thromboembolic risk factors [8, 9].

This is deemed to be due to the downregulation of interleukin 6 (IL-6) and IL-12 dependent inflammatory cascades, leaving an unaffected interferon level that transmits the strongest prothrombotic signals [8]. Nonetheless, the adverse effect is rare when being used in patients with rheumatoid arthritis [9]. Moreover, both COV-BARRIER and Adaptive COVID-19 Treatment Trial 2 (ACTT-2) showed that Baricitinib demonstrated a significant reduction in 28-day mortality in patients on oxygen supplements with no more side effects than the placebo [10-12].

However, caution still needs to be exercised to weigh the risks and benefits of using an immunomodulatory agent in a COVID-19 patient, considering other potential confounding factors such as the patient's comorbidities, immobilisation due to oxygen dependency and concomitant infections. In this case, it is inconclusive that the stroke is directly related to the pathogenesis of COVID-19 or partly attributed to Baricitinib. Hence, excluding COVID-19 patients with significant thrombotic risks from using immunomodulatory agents, hopefully to reduce the chance of a thrombotic event, will never be an easy decision to make.

In a recently published large external validation study on the IMPROVE-DD risk assessment model, it has been shown to be able to identify the risk of venous thromboembolism in hospitalised COVID-19 patients [13]. Conversely, the assessment of arterial thrombosis is still currently lacking. Perhaps, a validated assessment tool for risk stratification in evaluating a COVID-19 patient's thrombotic risks, balanced against the benefit of an immunomodulator that can also potentially result in detrimental effects, can be looked into so that potential candidates who may benefit the most from the pharmacotherapy can be identified.

IV. CONCLUSIONS

The hypercoagulable state of the COVID-19, coupled with other contributing variables, can put the patients at high risk of both venous and arterial thromboses. Hence, the treating clinicians need to weigh the risks and benefits of an immunomodulatory agent before prescribing it to avert fatal outcomes in COVID-19 patients. It can be beneficial in dampening the inflammatory pathways in COVID-19, but its potential prothrombotic risks must be carefully considered.

CONSENT TO PARTICIPATE

Written informed consent was obtained from the patient for the anonymized information to be published in this article.

CONFLICT OF INTERESTS

The authors declared no conflict of interest and did not receive any funding for this article.

ACKNOWLEDGEMENT

The authors would like to express their utmost gratitude to the patient and his family, who consented to his radiographs and history being used for the purpose of the publication despite the tremendous challenges they endured throughout the hospitalisation.

REFERENCES

- [1] Luo, W., Liu, X., Bao, K., & Huang, C. (2022). Ischemic stroke associated with COVID-19: a systematic review and meta-analysis. *Journal of Neurology*, 269(4), 1731–1740. <https://doi.org/10.1007/s00415-021-10837-7>
- [2] Tan, Y. K., Goh, C., Leow, A. S. T., Tambyah, P. A., Ang, A., Yap, E. S., Tu, T. M., Sharma, V. K., Yeo, L. L. L., Chan, B. P. L., & Tan, B. Y. Q. (2020). COVID-19 and ischemic stroke: a systematic review and meta-summary of the literature. *Journal of Thrombosis and Thrombolysis*, 50(3), 587–595. <https://doi.org/10.1007/s11239-020-02228-y>
- [3] Zakeri, A., Jadhav, A. P., Sullenger, B. A., & Nimjee, S. M. (2021). Ischemic stroke in COVID-19-positive patients: An overview of SARS-CoV-2 and thrombotic mechanisms for the neurointerventionalist. *Journal of NeuroInterventional Surgery*, 13(3), 202–206. <https://doi.org/10.1136/neurintsurg-2020-016794>
- [4] Nannoni, S., de Groot, R., Bell, S., & Markus, H. S. (2021). Stroke in COVID-19: A systematic review and meta-analysis. *International Journal of Stroke*, 16(2), 137–149. <https://doi.org/10.1177/1747493020972922>
- [5] Pawelczyk, M., Kaczorowska, B., & Baj, Z. (2017). The impact of hyperglycemia and hyperlipidemia on plasma P-selectin and platelet markers after ischemic stroke. *Archives of Medical Science*, 13(5), 1049–1056. <https://doi.org/10.5114/aoms.2017.65816>
- [6] Qureshi, A. I., Baskett, W. I., Huang, W., Shyu, D., Myers, D., Raju, M., Lobanova, I., Suri, M. F. K., Naqvi, S. H., French, B. R., Siddiq, F., Gomez, C. R., & Shyu, C. R. (2021). Acute Ischemic Stroke and COVID-19: An Analysis of 27 676 Patients. *Stroke*, March, 905–912. <https://doi.org/10.1161/STROKEAHA.120.031786>
- [7] Klein, A. P., Yarbrough, K., & Cole, J. W. (2021). Stroke, Smoking and Vaping: The No-Good, the Bad and the Ugly. *Annals of public health and research*, 8(1), 1104.
- [8] Kotyla, P. J., Engelmann, M., Giemza-Stokłosa, J., Wnuk, B., & Islam, M. A. (2021). Thromboembolic adverse drug reactions in janus kinase (Jak) inhibitors: Does the inhibitor specificity play a role? *International Journal of Molecular Sciences*, 22(5), 1–20. <https://doi.org/10.3390/ijms22052449>
- [9] Jorgensen, S. C. J., Tse, C. L. Y., Burry, L., & Dresser, L. D. (2020). Baricitinib: A Review of Pharmacology, Safety, and Emerging Clinical Experience in COVID-19. *Pharmacotherapy*, 40(8), 843–856. <https://doi.org/10.1002/phar.2438>
- [10] Kalil, A. C., & Stebbing, J. (2021). Baricitinib: the first immunomodulatory treatment to reduce COVID-19 mortality in a placebo-controlled trial. *The Lancet Respiratory Medicine*, 9(12), 1349–1351. [https://doi.org/10.1016/S2213-2600\(21\)00358-1](https://doi.org/10.1016/S2213-2600(21)00358-1)
- [11] Marconi, V. C., Ramanan, A. V., de Bono, S., Kartman, C. E., Krishnan, V., Liao, R., Piruzeli, M. L. B., Goldman, J. D., Alatorre-Alexander, J., de Cassia Pellegrini, R., Estrada, V., Som, M., Cardoso, A., Chakladar, S., Crowe, B., Reis, P., Zhang, X., Adams, D. H., Ely, E. W., ... Zirpe, K. (2021). Efficacy and safety of baricitinib for the treatment of hospitalised adults with COVID-19 (COV-BARRIER): a randomised, double-blind, parallel-group, placebo-controlled phase 3 trial. *The Lancet Respiratory Medicine*, 9(12), 1407–1418. [https://doi.org/10.1016/S2213-2600\(21\)00331-3](https://doi.org/10.1016/S2213-2600(21)00331-3)
- [12] Kalil, A.C., Patterson, T.F., Mehta, A.K., Tomashek, K.M., Wolfe, C.R., Ghazaryan, V., Marconi, V.C., Ruiz-Palacios, G.M., Hsieh, L., Kline, S. and Tapson, V., 2021. Baricitinib plus remdesivir for hospitalized adults with Covid-19. *New England Journal of Medicine*, 384(9), pp.795-807. <https://doi.org/10.1056/nejmoa2031994>
- [13] Spyropoulos, A. C., Cohen, S. L., Gianos, E., Kohn, N., Giannis, D., Chatterjee, S., Goldin, M., Lesser, M., Coppa, K., Hirsch, J. S., McGinn, T., & Barish, M. A. (2021). Validation of the IMPROVE-DD risk assessment model for venous thromboembolism among hospitalised patients with COVID-19. *Research and Practice in Thrombosis and Haemostasis*, 5(2), 296–300. <https://doi.org/10.1002/rth2.12486>