

Case Report

Pyogenic Granuloma of Inferior Turbinate in Children: Common Symptoms with a Rare Diagnosis

Nor Eyzawiah Hassan¹, Siti Nur Farhana Ariff², Shahrul Hitam², Nor Azirah Salahuddin¹, Siti Asmat Md Arepen¹

¹Otorhinolaryngology Head And Neck Surgery, Faculty of Medicine and Health Sciences, Universiti Sains Islam Malaysia (USIM).

²Department of Otorhinolaryngology, Ampang Hospital, Selangor, Malaysia.

Correspondence should be addressed to:

Siti Asmat Md Arepen; drsitiasmat@usim.edu.my

Article Info

Article history:

Received: 30 April 2021

Accepted: 26 July 2021

Published: 1 September 2021

Academic Editor:

Sharifah Najwa Syed Mohamad

Malaysian Journal of Science, Health

& Technology

MJoSHT2021, Volume 7, Special

Issue

eISSN: 2601-0003

[https://doi.org/](https://doi.org/10.33102/mjosht.v7iSpecial Issue.204)

10.33102/mjosht.v7iSpecial Issue.204

Copyright © 2021 Arepen S.A.M.D.

et al. This is an open access article

distributed under the Creative

Commons Attribution 4.0

International License, which permits

unrestricted use, distribution, and

reproduction in any medium,

provided the original work is

properly cited.

Abstract—Pyogenic granuloma (PG) is a rapidly growing benign lesion of the skin and mucous membrane. Its etiology is still unclear. It is suggested to have arisen either due to trauma or hormonal influences. Pyogenic granuloma is regularly found in the oral cavity. Even though it is rare, it does occur in the nasal cavity and a few cases of pyogenic granuloma have been reported among the paediatric population. We present a case of a 6-year-old boy, who presented with unilateral nasal blockage and recurrent epistaxis. The child has a history of allergic rhinitis and frequent nasal picking. Clinical examination revealed a small broad based reddish mass at the anterior part of the right inferior turbinate. The histopathological examination from complete excisional biopsy was consistent with pyogenic granuloma. Although pyogenic granuloma is relatively rare, we should raise suspicion in young patients who complain of progressive unilateral nasal blockage and recurrent epistaxis, with or without a history of trauma. Thorough clinical examination is adequate in small lesion thus sparing the need for radiological investigation for bigger and extensive lesions. Complete excision is the ultimate treatment to avoid recurrence.

Keywords: pyogenic granuloma, turbinates, epistaxis, child, nasal cavity, benign

I. INTRODUCTION

Pyogenic granuloma (PG) is a rapidly growing benign vascular proliferative tumour of the skin and mucous membrane. It is also known as lobular capillary hemangioma, epulis gravidarum (pregnancy tumour), and granulation tissue type hemangioma botryomycosis [1]. Although it occurs more often in the third decade of life, and in female, PG have been reported predominantly in male paediatric population [1]. We present a case of a 6-year-old boy with unilateral pyogenic granuloma of the inferior turbinate.

II. CASE REPORT

A 6-year-old boy presented with recurrent epistaxis and persistent right sided nasal blockage of one-month duration. It was associated with frequent rhinorrhoea and itchiness. The child had history of underlying allergic rhinitis. According to the parents, he had a bad habit of nose picking. External nasal examination was normal and cold spatula test showed slight reduced misting on the right side. Anterior rhinoscopy revealed a reddish mass in the right nasal cavity. On endoscopic examination, a broad-based reddish mass measuring approximately one centimetre in size was seen

arising from the anterior part of the right inferior turbinate. The mass was localised, well encapsulated, with smooth surface, not friable and had no contact bleeding on touch. No abnormality or similar finding was noted in the left nasal cavity and nasopharynx. Other head, neck and systemic examinations were unremarkable. Radiological investigation was not indicated as the origin and extension of the mass was clearly seen.

Endoscopic excision of the mass was done using cold method under general anaesthesia. The lesion was totally removed and haemostasis was secured using bipolar diathermy. The patient was discharged well on the next day. During follow up two months post excision, the operation site was well healed and there was no evidence of recurrence. Histopathological examination of the mass was consistent with pyogenic granuloma.

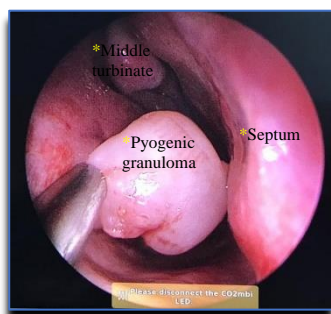


Fig. 1 Picture showing the mass arise from inferior turbinate

III. DISCUSSION

PG was first described in 1897 as human botryomycosis [2]. Clinically, the lesion appeared as necrotic white mass resembling pus. Therefore, the term “granuloma pyogenicum” was introduced by Hartzell in 1974 [3]. However, it is a misnomer because the histological characteristics is neither pyogenic nor granulomatous. Mills *et al.* have used the term “lobular capillary hemangioma” which is more appropriate and described the lesion as aggregates of capillaries arranged in one or more lobules [4]. However, the term “pyogenic granuloma” is still used in most scientific literature.

The oral cavity is the most common site involved in the head and neck region (62.4%). Although it is common in the head and neck region PG in the nasal cavity and paediatric group is rare [5]. Only 7-10% of patients had involvement of the nasal cavity where the anterior part of turbinate and anterior septal mucosa (Little’s Area) are the most commonly involved areas [5][6]. In our case, the location of the pyogenic granuloma occurred at the anterior part of the inferior turbinate.

A definite pathogenesis of pyogenic granuloma was unclear. Oral PG has shown an activation of mitogen-activated protein kinase/extracellular signal-regulated kinases (MAPK/ERK) pathway, but the driver molecular event remains to be elucidated [6]. However, the repetitive trauma of nose picking could be the possible mechanism associated with this patient. Other mechanisms that were suggested include hormonal influences, which is usually seen in pregnancy [7]. It has also been associated with the use of oral

contraceptive pills and anti-tubercular therapy [8]. The inflammatory process can also be stimulated by bone marrow transplant and reaction to graft [9]. Nevertheless, there could also be absence of associated risk factors or idiopathic as reported by Hassan NE *et. al* [10]. In the paediatric group, the aetiology in most of the cases reported was due to microtrauma.

Patients with PG may present with unilateral epistaxis (95%), nasal blockage (35%), nasal discharge (10%), facial pain (7.5%) and hyposmia (4%) [3]. Most of the literature reported that PG in children usually presented with epistaxis and nasal blockage. In our case, the patient also had recurrent epistaxis and persistent nasal blockage. Clinical examination may show a red to purplish mass which could be broad-based, lobulated or pedunculated. The size is usually variable, with a diameter less than 10 millimetres. Common complications include bleeding (72%) and ulceration (12%) [11]. For our patient, the mass was well capsulated with a smooth surface and there was no ulceration.

In this patient, radiological examination was unnecessary as the lesion was localized at the anterior part of the inferior turbinate with limited extension. The most commonly done imaging study is Computed Tomography (CT) scan which is usually indicated in cases of large unilateral lesions to look for its origin, involvement or extension to the skull base. In addition, it will provide any evidence of bony erosion to exclude malignancy and other differential diagnosis. On contrast-enhanced computed tomography (CECT), PG appeared as two distinct areas; a lobular intensely enhancing mass and an iso- or hypoattenuating cap of variable thickness around the intensely enhancing mass [12].

The mainstay of treatment is complete surgical excision of the lesion including removal of its base with or without embolization. Total excision by either classical or endoscopic surgical techniques have been recommended. Endoscopic approach provides better visualization and it allows the surgeon to remove the mass completely with optimal control of bleeding. The procedure can be done under local or general anaesthesia. In view of the patient’s age and to get the better view and control, surgical excision in our case was done via endoscopic approach under general anaesthesia. Excision under general anaesthesia is also recommended in cases with larger lesions and lesions that are located at or near to critical structures such as lamina papyracea. Novel treatment such as laser therapy, alitretinoin gel and sclerosing agent were also reported to provide satisfactory results [13].

Most of the journals rarely reported about the recurrence and if present it is usually due to incomplete excision. However, no malignant transformation had been reported to date [1].

IV. CONCLUSIONS

Pyogenic granuloma can arise in the nasal cavity as a complication of repeated micro-trauma, such as nose picking. Although it is rare in the nasal cavity and pediatric population, PG should be considered in this group of patients with history of epistaxis and nasal obstruction. Complete excision is the primary treatment to avoid recurrence.

CONSENT TO PARTICIPATE

Written informed consent was obtained from the patient for the anonymized information to be published in this article.

CONFLICT OF INTERESTS

The authors declare that there is no conflict of interest.

ACKNOWLEDGEMENT

We would like to thank the Director General of Health Malaysia for his permission to publish this article.

REFERENCES

- [1] Puxeddu, R., Berlucchi, M., Ledda, G. P., Parodo, G., Farina, D., & Nicolai, P. (2006). Lobular capillary hemangioma of the nasal cavity: a retrospective study on 40 patients. *American journal of rhinology*, 20(4), 480-484.
- [2] P., A. (1897). Botromycose Humain. *Rev Chir*, 18, 996-998.
- [3] H., M. B. (1974). Granulation pyogenicum. *J Cutan*, 22, 520-523.
- [4] Mills, S. E., Cooper, P. H., & Fechner, R. E. (1980). Lobular capillary hemangioma: the underlying lesion of pyogenic granuloma. A study of 73 cases from the oral and nasal mucous membranes. *The American journal of surgical pathology*, 4(5), 470-479.
- [5] Patrice, S. J., Wiss, K., & Mulliken, J. B. (1991). Pyogenic granuloma (lobular capillary hemangioma): a clinicopathologic study of 178 cases. *Pediatric dermatology*, 8(4), 267-276.
- [6] Pereira, T. D. S. F., de Amorim, L. S. D., Pereira, N. B., Vitória, J. G., Duarte-Andrade, F. F., Guimarães, L. M., ... & Gomez, R. S. (2019). Oral pyogenic granulomas show MAPK/ERK signaling pathway activation, which occurs independently of BRAF, KRAS, HRAS, NRAS, GNA11, and GNA14 mutations. *Journal of Oral Pathology & Medicine*, 48(10), 906-910.
- [7] Delbrouck, C., Chamiec, M., Hassid, S., & Ghanooni, R. (2011). Lobular capillary haemangioma of the nasal cavity during pregnancy. *The Journal of Laryngology & Otology*, 125(9), 973-977.
- [8] Kumar, R. A., Babu, M. M., Venkatarajamma, P. R., & Mishra, U. (2014). Pyogenic Granuloma of Nasal Septum: A Case Report and Review of Literature. *International Journal of Otolaryngology and Head & Neck Surgery*, 27.
- [9] Saravana, G. H. L. (2009). Oral pyogenic granuloma: a review of 137 cases. *British Journal of Oral and Maxillofacial Surgery*, 47(4), 318-319.
- [10] Hassan, N. E., & Goh, B. S. (2012). Pyogenic granuloma of the nasal septum: A rare cause of epistaxis. *Brunei International Medical Journal*, 8(6), 367-370.
- [11] Cordisco, M. R. (2009). Hemangiomas of infancy: epidemiology. In *Hemangiomas and Vascular Malformations* (pp. 17-21). Springer, Milano.
- [12] Lee, D. G., Lee, S. K., Chang, H. W., Kim, J. Y., Lee, H. J., Lee, S. M., ... & Woo, S. (2010). CT features of lobular capillary hemangioma of the nasal cavity. *American journal of neuroradiology*, 31(4), 749-754.
- [13] Rai, S., Kaur, M., & Bhatnagar, P. (2011). Laser: a powerful tool for treatment of pyogenic granuloma. *Journal of cutaneous and aesthetic surgery*, 4(2), 144.