

Case Report

A Rare Case of a Maxillary First Molar with Three Mesio-Buccal Canals

Aws Hashim Ali Al-Kadhim¹, Sarah Taha Yousif², Nusima Mohamed¹

¹Faculty of Dentistry, Universiti Sains Islam Malaysia, Kuala Lumpur, 55100, Malaysia.

²WeCare Medical clinic, Kuala Lumpur, 55100, Malaysia.

Correspondence should be addressed to:

Aws Hashim Ali Al-Kadhim; awshashim@usim.edu.my

Article Info

Article history:

Received: 28 April 2021

Accepted: 28 July 2021

Published: 1 September 2021

Academic Editor:

Ahmad Izzat Ahmad Tajjudin

Malaysian Journal of Science, Health & Technology

MJoSHT2021, Volume 7, Special

Issue

eISSN: 2601-0003

<https://doi.org/>

10.33102/mjosht.v7iSpecial Issue.192

Copyright © 2021 AH Al-Kadhim et

al. This is an open access article

distributed under the Creative

Commons Attribution 4.0

International License, which permits

unrestricted use, distribution, and

reproduction in any medium,

provided the original work is

properly cited.

Abstract— The maxillary first molar has the highest failure rate of root canal treatment, with missing canals being one of the most common causes of failure. This case illustrates the wide range of root canal anatomy in the maxillary first molar. Therefore, during endodontic care, anatomical variation should be taken into account by radiographic and clinical evaluations.

Keywords— root canal treatment, maxillary first molar, mesiobuccal canals.

I. INTRODUCTION

Knowing the morphological of root canal anatomy plays a significant role in root canal treatment [1]. However, root canal treatment is challenging due to anatomical variation in root canal systems [2]. However, with the advancement of radiographical examination and the introduction of cone beam (CT), microscope, and the increased awareness among dental practitioners towards such variations, root canal treatment success rate had increased dramatically [3].

Maxillary first permanent molar is among the first teeth to erupt into the mouth. Therefore, the possibilities of the need for root canal treatment are higher [4,5]. In addition, when patients continue to experience symptoms despite a root-filled tooth that appears to be adequate on radiographic examination, a missing canal may be the cause. About 78% of teeth show

two canals in the mesiobuccal root inside maxillary first molars [6].

II. CASE REPORT

A twenty-year-old Malay female was referred to a restorative specialist clinic at the Faculty of Dentistry, Universiti Sains Islam Malaysia (USIM). The chief complaint being sharping disturbing pain upon drinking cold beverages and two episodes of night pain on the upper left side that disturbs her sleep. However, the patient could not identify the involved tooth. Medical and dental history was not contributory.

On clinical examination, the patient's oral hygiene was fair with plaque score >50 percent and calculus on the upper molars' buccal surface, left and right side, and lingual surface of the lower anterior teeth. The upper left first permanent molar 26 has ICDAS code 5, and the tooth was

tender to percussion and palpation. A pulp sensibility test was performed and the tooth had a hyper response to the electrical pulp test. The pain could not be relieved only after the administration of local anaesthesia. Following the American Association of Endodontist (AAE), a diagnosis of irreversible pulpitis on tooth 26 was established. Endodontic treatment was agreed as a treatment choice.

The tooth was anaesthetized with 2.2ml 3% mepivacaine containing 1:100 000 adrenaline (*Scandonest, Lancaster, United Kingdom*), rubber dam isolation was applied (*Blossom, Union City*). Caries was removed, and endodontic access was created, as shown in Figure 1.

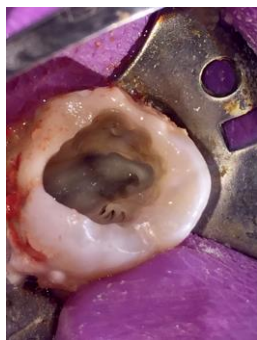

Figure 1: Access opening performed after pre endodontic composite build-up, where three canal orifices noted at the mesiobuccal root.

The pre-endodontic restoration was done using composite (*Filtek Z350, 3M ESPE, Minnesota*). Five canals were located; three at the mesiobuccal root, one at the distobuccal root and one at the palatal root under a dental operating microscope (*OMS2380, Zumax Medical, Suzhou, China*).

Glide path was achieved at distal and palatal canals with k file size 8 (*DentsplyMaillefer, Ballaigues, Switzerland*). Mesial canals were enlarged coronally and k file of size 6, 8 and 10 were used. Irrigation with 17% EDTA was used to dissolve the smear layer and to lubricate the canals during the procedure. Working length was confirmed for all canals using apex locator and radiographic examinations shown in Figure 2.

The three mesiobuccal canals united at the apical third of the mesiobuccal root, which had curvature toward the distal surface. All mesiobuccal canals were shaped and cleaned until size 25 with a 4% taper. Then, both distal and palatal canals were cleaned and shaped until size 30 with a 6% taper. Copious irrigation was performed with 5.2% sodium hypochlorite (NaOCl). Non-setting calcium hydroxide (*Ultracal XS, Ultradent, Utah, USA*) was subsequently placed intracanal and left for 14 days, and the temporary filling was placed with kalzinol (*Dentsply, North Carolina, USA*).

After 14 days, no symptom was reported. The tooth was isolated and temporary filling (kalzinol) removed. Calcium hydroxide was removed by irrigation with 5.2% (NaOCl). Master Gutta Percha was inserted, and tug back was confirmed. A periapical radiograph was taken, which showed all fit reaching full working length. Final irrigation was done with 5.2% NaOCl, normal saline and 17% EDTA with sonic activation. Then, canals were dried with the paper point. Obturation was then done by hydraulic condensation technique using single cone matched gutta-percha and bioceramic sealer (*Ceraseal, Metabiomed, Cheong Ju, South*

Korea). Post obturation radiograph was taken, as shown in Figure 3.

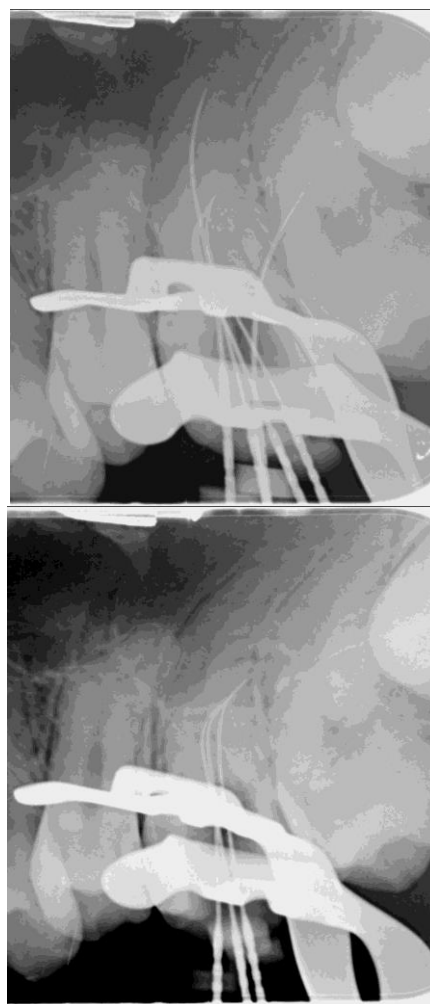


Figure 2: Periapical radiograph: Evidence of 3 mesiobuccal canals noted at the mesio-buccal root.

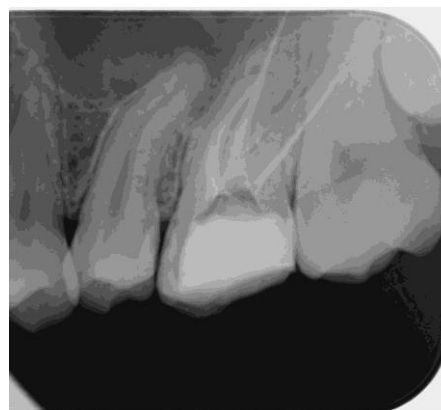

Fig 3: Post obturation radiograph.

The semi-permanent filling was placed with composite (*Filtek Z350, 3M ESPE, Minnesota*). The patient was referred back for cuspal coverage, where a recall appointment after six months was made to monitor healing progression.

III. DISCUSSION

One of the most frequent causes of failure to perform root canal filling in maxillary permanent first molars has been linked to the inability to identify extra canals, specifically in the mesiobuccal root, resulting in many studies and investigations than any other tooth in the oral cavity [7].

Maxillary first molar has many variations in its root canal anatomy in relation to a wide range of occurrence of the number of canals and roots [7, 8]. The mesiobuccal root of the maxillary first molar is long mesiopalatally, in contrast to the distobuccal root, which is circular in cross-section. This anatomical distinction could explain why the mesiobuccal root has a higher incidence of multiple canals [9,10]. According to recent studies done on the Malaysian population, maxillary first molar showed two mesiobuccal canals in around 45% of the population. There were no records regarding the incidence of three canals in the mesiobuccal root [11, 12].

Repeated radiographic examinations from various angles to examine the pulp floor with a sharp explorer was performed. This was done using ultrasonic tips to triumphing between the grooves. Here, observing the haemorrhagic points are a few effective methods for identifying root orifices [13, 14].

The dentist's expertise is crucial in locating and navigating complex canals in the MB root of maxillary molars favouring the experienced operator [15]. Therefore, dentists must devote more time to the appointment to locate additional canals. If the endodontic reamer/file is off-centred during exploration and negotiation or in the working length radiograph, the dentist should suspect the existence of additional canals in the root [16, 17]. The third canal was located in this case report by modifying the outline of the access cavity from a common triangular outline to a square or rhomboidal shape. This practice allowed for straight-line visualization, full pulp chamber debridement as well as identify and negotiate the MB2 and MB3 canals in the mesiobuccal root of the maxillary first molar. The relative ease with which the third canal was identified in this case may be attributed to the patient's age, as well as the use of an endodontic microscope and modified access preparation [18].

According to recent research, new techniques supported by endodontic microscope and high-intensity optic illumination have reported better success rates of identifying and locating extra canals in the mesiobuccal root of maxillary molars [19].

If the tooth is not thoroughly explored, the existence of these extra canals can be overlooked, resulting in treatment failure. In questionable situations, advanced imaging technologies such as CBC can be used as a supplementary method for detecting and managing variations in root canal morphology [13]. In the present case, the variable anatomy was clearly depicted by radiographs of various angulations and clinical examination of the pulp chamber surface. These imaging modalities can increase the patient's effective dose of radiation while providing excellent insight into the anatomical variations of the root or root canal configuration [12]. The clinician should have a thorough knowledge in the field of root canal morphology and its variation. In terms of the number of canals, the maxillary molar has a wide range of variation. Identifying the extra canal(s) and their proper cleaning, shaping, and sealing determine the prognosis of first

molars. Treatment failure may result from a failure to identify and treat a canal [19].

IV. CONCLUSION

The root canal system of the maxillary first molar can be complicated, where failure to locate all canals will decrease the long-term success rate of root canal treatment. This report showed that dentist should be knowledgeable and conscious of the anatomic variation in the root canal morphology, even though the frequency of having three mesial buccal canals in the maxillary first molar is rare

CONSENT TO PARTICIPATE

Written informed consent was obtained from the patient for publication of this case report and any accompanying images.

CONFLICT OF INTERESTS

The authors declare that there is no conflict of interest.

ACKNOWLEDGEMENT

We would like to thank the Faculty of Dentistry, Universiti Sains Islam Malaysia (USIM) for supporting this work.

REFERENCES

- [1] Benjamin, K. A., & Dowson, J. (1974). Incidence of two root canals in human mandibular incisor teeth. *Oral Surgery, Oral Medicine, Oral Pathology*, 38(1), 122-126.
- [2] Weine, F. S., Healey, H. J., Gerstein, H., & Evanson, L. (1969). Canal configuration in the mesiobuccal root of the maxillary first molar and its endodontic significance. *Oral Surgery, Oral Medicine, Oral Pathology*, 28(3), 419-425.
- [3] Neelakantan, P., Subbarao, C., Ahuja, R., Subbarao, C. V., & Gutmann, J. L. (2010). Cone-beam computed tomography study of root and canal morphology of maxillary first and second molars in an Indian population. *Journal of endodontics*, 36(10), 1622-1627.
- [4] Al Shalabi, R. M., Omer, O. E., Glennon, J., Jennings, M., & Claffey, N. M. (2000). Root canal anatomy of maxillary first and second permanent molars. *International endodontic journal*, 33(5), 405-414.
- [5] Hartwell, G., & Bellizzi, R. (1982). Clinical investigation of in vivo endodontically treated mandibular and maxillary molars. *Journal of endodontics*, 8(12), 555-557.
- [6] Kulid, J. C., & Peters, D. D. (1990). Incidence and configuration of canal systems in the mesiobuccal root of maxillary first and second molars. *Journal of endodontics*, 16(7), 311-317.
- [7] Verma, P., & Love, R. M. (2011). A Micro CT study of the mesiobuccal root canal morphology of the maxillary first molar tooth. *International endodontic journal*, 44(3), 210-217.
- [8] Degerness, R. A., & Bowles, W. R. (2010). Dimension, anatomy and morphology of the mesiobuccal root canal system in maxillary molars. *Journal of endodontics*, 36(6), 985-989.

- [9] Baratto Filho, F., Zaitter, S., Haragushiku, G. A., de Campos, E. A., Abuabara, A., & Correr, G. M. (2009). Analysis of the internal anatomy of maxillary first molars by using different methods. *Journal of endodontics*, 35(3), 337-342.
- [10] Ferguson, D. B., Kjar, K. S., & Hartwell, G. R. (2005). Three canals in the mesiobuccal root of a maxillary first molar: a case report. *Journal of endodontics*, 31(5), 400-402.
- [11] Al-Kadhim, A. H., Rajion, Z. A., Malik, N. A., & Bin Jaafar, A. (2017). Morphology of maxillary first molars analyzed by cone-beam computed tomography among Malaysian: variations in the number of roots and canals and the incidence of fusion. *International Medical Journal Malaysia*.
- [12] Abd Latib, A. H., Nordin, N. F., & Alkadhim, A. H. (2015). CBCT diagnostic application in detection of mesiobuccal canal in maxillary molars and distolingual canal in mandibular molars: a descriptive study. *of*, 3, 2.
- [13] Trope, M., Elfenbein, L., & Tronstad, L. (1986). Mandibular premolars with more than one root canal in different race groups. *Journal of endodontics*, 12(8), 343-345.
- [14] Fogel, H. M., Peikoff, M. D., & Christie, W. H. (1994). Canal configuration in the mesiobuccal root of the maxillary first molar: a clinical study. *Journal of endodontics*, 20(3), 135-137.
- [15] Vertucci, F. J. (1984). Root canal anatomy of the human permanent teeth. *Oral surgery, oral medicine, oral pathology*, 58(5), 589-599.
- [16] Cleghorn, B. M., Christie, W. H., & Dong, C. C. (2006). Root and root canal morphology of the human permanent maxillary first molar: a literature review. *Journal of endodontics*, 32(9), 813-821.
- [17] Vertucci, F. J. (2005). Root canal morphology and its relationship to endodontic procedures. *Endodontic topics*, 10(1), 3-29.
- [18] Matherne, R. P., Angelopoulos, C., Kulild, J. C., & Tira, D. (2008). Use of cone-beam computed tomography to identify root canal systems in vitro. *Journal of endodontics*, 34(1), 87-89.
- [19] Corcoran, J., Apicella, M. J., & Mines, P. (2007). The effect of operator experience in locating additional canals in maxillary molars. *Journal of Endodontics*, 33(1), 15-17.