

Article

The Efficacy of Reciproc Blue® For Canal Cleanliness Following the Retreatment of Maxillary First Molar: In Vitro Analysis

Mohd Nazrin Isa¹, Aws Hashim Ali Al-Kadhim¹, Azlan Jaafar¹

¹Faculty of Dentistry, Universiti Sains Islam Malaysia (USIM), 55100, Kuala Lumpur, Malaysia

E-mail: mohdnazrin@usim.edu.my

Abstract—Nonsurgical retreatment involves removing mechanical barriers such as gutta-percha to achieve proper cleaning and disinfection. The complexity of the anatomy of molar tooth gives challenge in retreatment procedure. Thus, this study evaluates the amount of residual gutta-percha after retreatment with rotary files (Reciproc Blue®) from each maxillary first molar canal using cone-beam computed tomography (CBCT) and the time required to accomplish it. Nine freshly extracted maxillary molars were instrumented and obturated. Preoperative CBCT was taken, and retreatment was done using Reciproc Blue®. CBCT was taken post retreatment, and the residual volume percentage of gutta-percha from each canal was calculated. The total retreatment time was recorded, and the data were statistically analyzed. The result shows no statistically significant difference in the amount of residual filling material in mesiobuccal, distobuccal, and palatal canal for maxillary first molar and total time used for retreatment with Reciproc Blue® system.

Keywords— Retreatment; Reciproc Blue; cleanliness canal walls.

I. INTRODUCTION

The principle in endodontic therapy relies on eliminating irritation of the periapical tissues by root canal infection. This can be achieved by chemo-mechanical debridement and complete sealing of the root canal system [1]. The two main leading causes of endodontic failure are the inability to eliminate microorganisms present during initial treatment and reintroducing microorganisms into the root canal system after completion of the endodontic treatment [2][3]. Nonsurgical retreatment is the method of choice in dealing with endodontic failure whenever possible as it is the most conservative method [4].

To achieve proper cleaning and disinfection during the retreatment procedure, instruments and irrigating solutions must be ensured to reach the entire root canal system. This is vital so that the mechanical barrier such as gutta-percha can be completely removed as any remaining residue contains microbial load, which will affect the treatment outcome [2].

Molars have shown a lower percentage of success rates in nonsurgical retreatment compared to premolars and anterior teeth. This is because the molar tooth's complexity, such as its

anatomical curve root structure, makes it difficult to eliminate it [5][6].

Several methods have been proposed mechanically for gutta-percha removals, such as using Hedstrom file, nickel-titanium rotary files, gates glidden, sonic and ultrasonic tips. However, several studies prove rotary nickel-titanium for its efficiency, fast and safe during gutta-percha removal [7][8].

VDW Company manufactured Reciproc Blue® from Munich, Germany, with a single file reciprocating system. It consists of R25 with a 0.25mm tip size and 8% taper, R40 with 0.4mm tip size and 6% taper, as well as R50 with a 0.50mm tip size and 5% taper. Heat treatment is used in its manufacturing process, which is known to modify the M-wire instrument's structure at its molecular level. This approach contributes towards its higher flexibility and resistance in cyclic fatigue. With an S-shaped cross-section, two cutting edges, and a non-cutting tip, it can also be used to remove gutta-percha in a retreatment procedure, as stated by the manufacturer. Therefore, this study evaluates the amount of residual gutta-percha after retreatment with rotary files (Reciproc Blue®) from each maxillary first molar canal using cone-beam computed tomography (CBCT) and the time required accomplishing it.

II. MATERIAL AND METHOD

A. Specimen Preparation

Nine freshly extracted first maxillary molars, which include 27 canals, were used. The inclusion criteria include first maxillary molar teeth with an intact crown and root with no second mesiobuccal canal. Exclusion criteria were the first maxillary molar with a second mesiobuccal canal and an abnormal tooth morphology such as taurodont tooth. Soft tissue and calculus were mechanically removed from the root surfaces, and the teeth were stored in a 2.5% sodium hypochlorite (NaOCl) solution for disinfection. Caries-free and access cavities were done using a high-speed diamond bur with water-cooling. This study obtained an ethical approval from the Universiti Sains Islam Malaysia's research ethical committee with the code number USIM/JKEP/2020-96.

On the other hand, pre-endobuild-up was done with composite filling (Tetric N Ceram, Ivoclar Vivadent, FL Schaan, Liechtenstein). The apical patency was achieved with 10 K-file (Dentsply Maillefer, Ballaigues, Switzerland). The working length was established at 1 mm short of the apical foramen. Cleaning and shaping all canals were completed using Protaper(DentsplyMaillefer, Ballaigues, Switzerland) manual instruments. The mesiobuccal canal was prepared to size F1, the distobuccal canal until F2, while the palatal canal was prepared until F4. All canals were irrigated with 17% EDTA followed by 2ml of 2.5% NaOCl as final irrigation. Subsequently, the root canals were dried with absorbent paper points.

The root canals were filled with cold lateral condensation of gutta-percha, and root canal sealer AH 26® was used (Dentsply De Trey, Konstanz, Germany) by an operator. A master gutta-percha cone was selected, and a tug back was checked. The AH 26® sealer was mixed according to the manufacturer's instructions, and the master cone was coated with the sealer and positioned into the canal. After that, accessory gutta-percha of sizes 20 and 25 were laterally compacted using a finger spreader (Dentsply Maillefer, Ballaigues, Switzerland) until it could not be introduced more than 3mm into the canal. A heated plugger was used to remove 2mm of the gutta-percha coronally. The root canal filling was compacted vertically with a cold plugger. The filling was placed using Kalzinol (Dentsply Sirona, Charlotte, USA). The specimen's incubation took up to 4 weeks with a temperature of 37°C at 100% humidity to achieve a complete setting.

All specimens were placed in wax and scanned using CBCT (PlanmecaPromax® 3D Mid, Helsinki, Finland) for the preoperative investigation followed by these exposure conditions: 100µm voxel size, 360° rotation, 90kV tube voltage, 10 mA tube current, 12s scanning time, and a field of view (FOV) of 40*50mm.

B. Retreatment Technique

The retreatment instrument was carried out into the canal using an electric endomotor (E-Connect S, Eighteeth, Jiangsu, China). Speed and torque were set for each instrument according to the manufacturer's instructions. The specimens were retreated using Reciproc Blue® (VDW, Munich, Germany). The retreatment was carried out with R40 for the palatal (P) canal and R25 file for mesiobuccal (MB) and distobuccal (DB). All the files were used with the motor's reciproc program.

No solvent was required to aid the procedure in removing the root filling. For re-instrumentation, each file was irrigated with 1 mL of 2.5% NaOCl in between. A complete gutta-percha removal was achieved when there was no evidence filling material on the files. Time taken to complete the retreatment was recorded, and the final irrigation was carried out with NaOCl. Later, each specimen was repositioned on a wax plate and scanned with CBCT. Volumetric analysis was completed with sagittal slices, and a polygonal tool in all of the sections was required in the outline of the region of interest (ROI) process. In reconstructing and calculating the selected areas' volume, it required PlanmecaRomexis®, where the measurement was conducted twice in two different time settings in establishing reproducibility (Figure 1).

C. Observer Calibration

Data reliability assessment is performed using an intra examiner calibration. Observer's calibration was done by two dentists with assistance from a radiologist. All examiners followed the same written guideline, which was given to them prior to the procedure. This was conducted by evaluating five random scans in estimating the volume.

The assessment for the images was done twice, including a 1-week interim between evaluations. Any disagreement encountered in the image interpretation was discussed. For any situation that could not achieve consensus, a radiologist with endodontic experience would assist the decision-making process.

D. Statistical Analysis

SPSS version 24 for Windows (SPSS, Chicago, IL, USA) was used as the statistical evaluation of the results. One-way ANOVA was conducted in comparing the residual root canal filling material and retreatment time between the canals. The significant value was set at a level of less than 0.05.

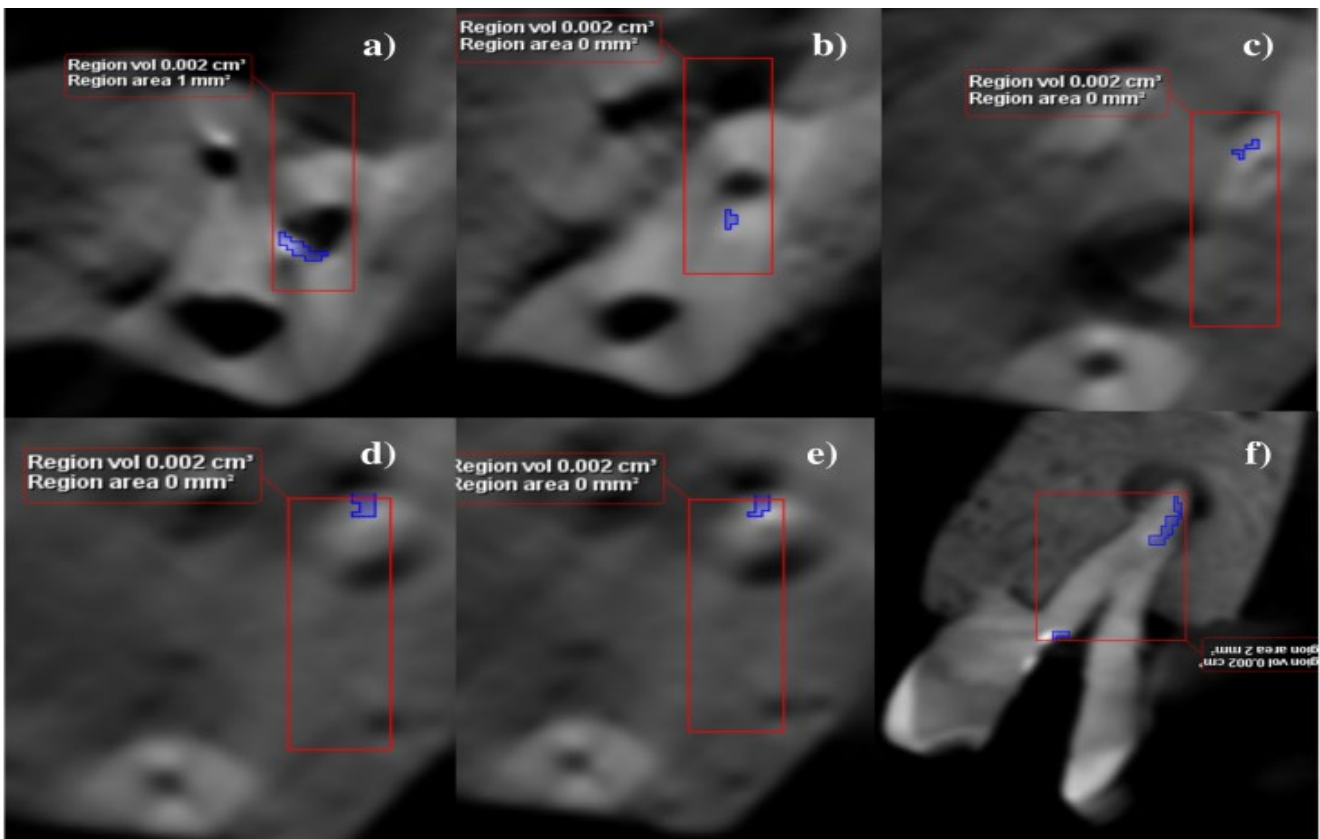


Fig. 1: (a-e) Image shows several mesiobuccal canal slices from coronal to apical with ROI marked after retreatment. (f) Image from sagittal view with ROI with its volume estimation.

III. RESULT

The mean percentage volumes of residual filling material in mesiobuccal, distobuccal, and palatal canals were 15.06%, 1.77%, and 1.89%, respectively (Table 1). Despite the highest percentage of residual filling material scored by the mesiobuccal canal, there was no significant difference between the three types of canals ($p=0.083$). No canals are exempted from showing completely clean from filling material (Fig. 2).

TABLE I
PERCENTAGE VOLUME RESIDUAL FILLING MATERIAL IN DIFFERENT CANAL ON FIRST MAXILLARY MOLAR

Type of Canal	Percentage Volume		<i>p</i> -value
	Mean±SD	Median (IQR)	
MB	15.06±20.78	6.82 (22.31)	0.083
DB	1.77±4.12	0.00 (1.14)	
P	1.89±3.22	0.99 (2.49)	

The mean time required for retreatment of the mesiopalatal canal was 271.89 seconds, 246.11 seconds for the distobuccal canal, and 414.89 seconds for the palatal canal (Table II). However, no significant difference was found between the canal retreatment time ($p=0.088$).

TABLE II
RETREATMENT TIME (S) OF DIFFERENT CANAL ON FIRST MAXILLARY MOLAR

Type of Canal	Retreatment time (s)		<i>p</i> -value
	Mean ± SD	Median (IQR)	
MB	271.89±117.37	240 (185)	0.088
DB	246.11±131.55	240 (168)	
P	414.89±227.06	420 (382)	

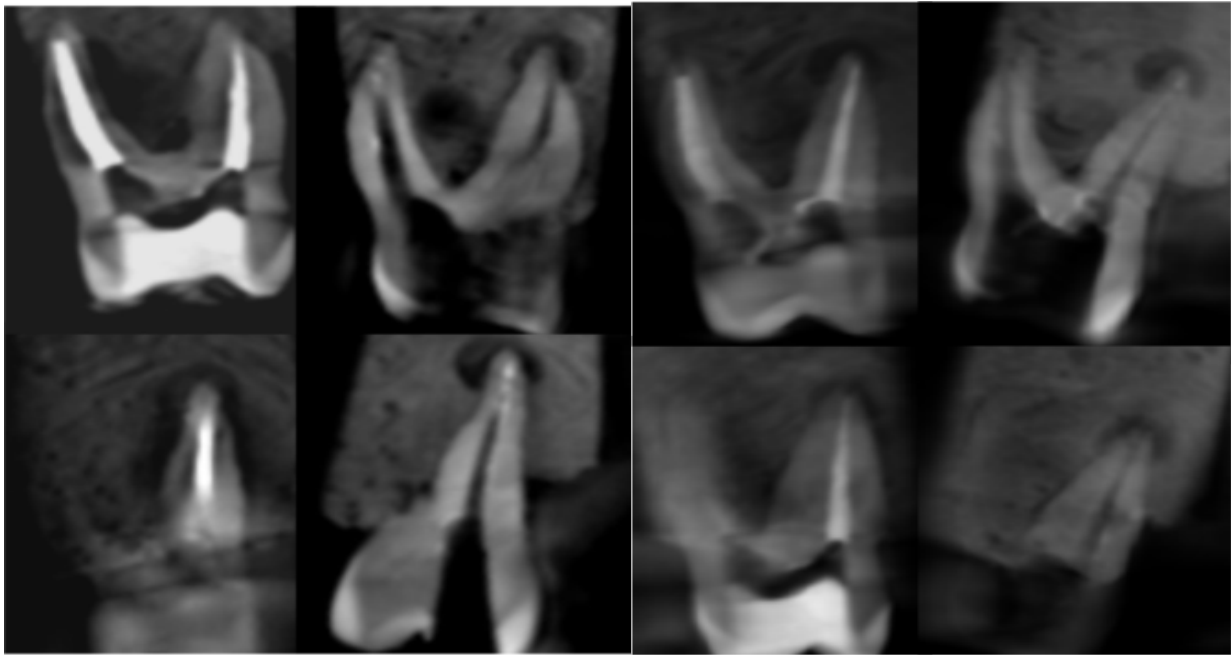


Fig. 2: Sagittal view before and after retreatment

IV. DISCUSSION

Multirrooted teeth were chosen in this study as they represent the actual situation in a clinical setting. Endodontic therapy's high failure rate is seen in multirrooted teeth compared to single-rooted teeth due to the complex anatomy [5].

As Ma J et al. (2012) stated, only the rotary file is used during gutta-percha removal to confirm the actual technique effectiveness. It is used as a standard procedure during this study without involving any solvents or other instruments used. According to microscopic and radiographic evaluations, the solvent used, such as chloroform, did not contribute to hand and rotary files' performance improvement in filling material removal. In fact, solvents may contribute to forming a fine layer of softened gutta-percha that can cause sulcus, isthmus, lateral canals obliteration, and any irregularities that cause difficulty to remove filling material. In addition, chloroform-softened gutta-percha is likely to be distributed throughout the canal, leading to a 'filmy appearance' on the canal walls [9].

Ideally, achieving complete removal of mechanical barriers such as gutta-percha is necessary to properly clean and disinfect during retreatment. The residual gutta-percha, which contains microbial load, will affect the treatment outcome [2]. Our study conclusion is in concordance with several previous studies [10] [11] [12] [13], where despite retreatment has been done, no canals can be totally free from gutta-percha. Considering the anatomical variation, whether the root canal is straight [14][15], oval [16], or curved [17][18], the conclusion remains the same. In other studies,

it was estimated that about 10-49% of root canal walls had stayed uninstrumented post-retreatment [19][20].

In this present study, the finding is consistent with the previous study by Yilmaz et al. (2018). The mesiobuccal canal shows the highest percentage of remaining gutta-percha than the distobuccal and palatal canal [13]. The residual root-filling material was huge in the apical region of curved canals in the mesial roots [21]. Removing filling material and instrumentation is more challenging for buccal canals in view of their curved anatomy than straight canals such as palatal canals. Apart from that, in a curved canal setting, there is a higher tendency for a fracture, file distortion, or root canal morphology alteration to take place [22].

Numerous studies show the effectiveness of Reciproc Blue® in retreatment. For example, De deus et al. compared the XP-endo Shaper, Reciproc Blue®, and M wire Reciproc to remove filling material in oval-shaped canals. The finding indicates that these systems show equal effectiveness in gutta-percha removal [23]. In addition, no significant difference was shown in gutta-percha removal efficiency and retreatment time between Protaper Gold and Reciproc Blue® [24]. Bago et al. (2020) researched to compare Reciproc Blue®, M-Wire Reciproc, Protaper Universal Retreatment, Protaper Gold, and Waveone Gold to remove root filling material in the curved canal. They revealed that there was no significant difference between them [25]. The superior ability of Reciproc Blue® in the retreatment process is attributed to its instrumental design of an S-shaped cross-section with sharp cutting edges, non-cutting tip, and a large chip space [26].

Our current study shows no significant difference in terms of retreatment time between all types of the canal. However, other factors that should be considered include the type of obturation, operator experience, and retreatment technique.

V. LIMITATION OF STUDY

Ideally, a micro-CT will show a better resolution and more accurate volume estimation results than cone-beam computed tomography (CBCT). This can be due to the artifact from a radiopaque material such as gutta-percha. However, due to the limited clinical availability, CBCT was used in this study [27].

V. CONCLUSION

Considering our study limitation, no canals are exempted from showing completely clean from filling material. There was no statistically significant difference in the amount of residual filling material in the mesiobuccal, distobuccal, and palatal canal for maxillary first molar and total time used for retreatment with Reciproc Blue® system.

ACKNOWLEDGEMENT

The authors would like to thank the Faculty of Dentistry, Universiti Sains Islam Malaysia, for providing all facilities and equipment for this research.

CONFLICT OF INTEREST

The authors declare that there is no conflict of interest regarding the publication of this paper.

REFERENCES

- [1] Bergenholtz G, Lekholm U, Milthorpe R, et al. Retreatment of endodontic fillings. *Scand J Dent Res* 1979;87:217–24.
- [2] Allen RK, Newton CW, Brown CE, Jr: A statistical analysis of surgical and non-surgical endodontic retreatment cases *J Endod* 15:261, 1989
- [3] Sjogren U, Figdor D, Persson S, Sundqvist G: Influence of infection at the time of root filling on the outcome of endodontic treatment of teeth with periapical periodontitis. *IntEndod J* 30:297,1997
- [4] Lovdahl PE. Endodontic retreatment. *Dental Clinics of North America*. 1992 Apr;36(2):473-490.
- [5] Imura, Noboru & Pinheiro, Ericka & Gomes, Brenda & Zaia, Alexandre & Ferraz, Caio & Souza-Filho, Francisco. The Outcome of Endodontic Treatment: A Retrospective Study of 2000 Cases Performed by a Specialist. *Journal of Endodontics*. 33. 1278-82. 2007
- [6] Al-Kadhim, A. H., Rajion, Z. A., AB Malik, N., & Jaafar, A.. Morphology of Maxillary First Molars Analyzed by Cone-Beam Computed Tomography among Malaysian: Variations in the Number of Roots and Canals and the Incidence of Fusion. *IIUM Medical Journal Malaysia*, 16(2), 2020.
- [7] Hülsmann M, Bluhm V. Efficacy, cleaning ability and safety of different rotary NiTi instruments in root canal retreatment. *IntEndod J* 2004;37:468–76.
- [8] Masiero, A.V. and Barletta, F.B., Effectiveness of different techniques for removing gutta-percha during retreatment. *International Endodontic Journal*, 38: 2-7. 2005.
- [9] Ma J, Al-Ashaw AJ, Shen Y, et al. Efficacy of ProTaper Universal Rotary Retreatment system for gutta-percha removal from oval root canals: a micro-computed tomography study. *J Endod* 2012;38:1516–20.
- [10] Gu LS, Ling JQ, Wei X, et al. Efficacy of ProTaper Universal rotary retreatment system for gutta-percha removal from root canals. *Int Endod J* 2008;41:288–95.
- [11] Reodig T, Hausdeorfer T, Konietzschke F, et al. Efficacy of D-RaCe and ProTaper Universal Retreatment NiTi instruments and hand files in removing gutta-percha from curved root canals: a micro-computed tomography study. *Int Endod J* 2012;45: 580–9
- [12] Somma F, Cammarota G, Plotino G, et al. The effectiveness of manual and mechanical instrumentation for the retreatment of three different root canal filling materials. *J Endod* 2008;34:466–9.
- [13] Yilmaz F, Koç C, Kamburoğlu K, Ocak M, Geneci F, Uzuner MB, Çelik HH. Evaluation of 3 Different Retreatment Techniques in Maxillary Molar Teeth by Using Micro-computed Tomography. *J Endod*. 2018 Mar;44(3):480-484.
- [14] Crozeta BM, de Sousa-Neto MD, Leoni GB et al. Micro-computed tomography study of filling material removal from oval-shaped canals by using rotary, reciprocating and adaptive motion systems. *Clinical Oral Investigation* 2016; 45, 793–7.
- [15] Canali LCF, Duque JA, Vivian RR, Bramante CM, So MVR, Duarte MAH, Comparison of efficiency of the retreatment procedure between Wave One Gold and Wave One systems by Micro-CT and confocal microscopy: an in vitro study. *Clinical Oral Investigation* 2019; 23, 337–53.
- [16] Bago I, Suk M, Katic M, Gabric D, Anic I. Comparison of the effectiveness of various rotary and reciprocating systems with different surface treatments to remove gutta-percha and an epoxy resin-based sealer from straight root canals. *International Endodontic Journal* 2019; 52, 105–13.
- [17] Marfisi K, Mercad_e M, Plotino G, Clavel T, Duran-Sindreu F, Roig M, Efficacy of Reciproc and profile instruments in the removal of gutta-percha from straight and curved root canals ex vivo *Journal of Oral and Maxillofacial Research* 6, el, 2015.
- [18] Crozeta BM, de Sousa-Neto MD, Leoni GB et al. Micro-computed tomography study of filling material removal from oval-shaped canals by using rotary, reciprocating and adaptive motion systems. *Clinical Oral Investigation* 2016; 45, 793–7.
- [19] Siqueira JF Jr, Alves FR, Versiani MA et al. Correlative bacteriologic and micro-computed tomographic analysis of mandibular molar mesial canals prepared by self-adjusting file, reciproc, and twisted file systems. *Journal of Endodontics* 2013;39, 1044–50.
- [20] Drukteinis S, Peculiene V, Dummer PMH, Hupp J, Shaping ability of BioRace, ProTaper Next and Genius nickel-titanium instruments in curved canals of mandibular molars: a Micro-CT study. *International Endodontic Journal* 2019; 52, 86–93.
- [21] Abramovitz I, Relles-Bonar S, Baransi B, et al. The effectiveness of a self-adjusting file to remove residual gutta-percha after retreatment with rotary files. *Int Endod J* 2012;45:386–92.
- [22] Schirmeister JH, Wrbas KT, Schneider FH, et al. Effectiveness of a hand file and three nickel-titanium rotary instruments for removing gutta-percha in curved root canals during retreatment. *Oral Surg Oral Med Oral Pathol Oral Radiol Endod* 2006;101:542–7.
- [23] De-Deus G, Belladonna FG, Zuolo AS, Cavalcante DM, Simões Carvalho M, Marinho A, Souza EM, Lopes RT, Silva EJNL. 3-dimensional Ability Assessment in Removing Root Filling Material from Pair-matched Oval-shaped Canals Using Thermal-treated Instruments. *J Endod*;45(9), 2019.
- [24] Faus-Matoses V, Pasarín-Linares C, Faus-Matoses I, Foschi F, Sauro S, Faus-Llácser VJ. Comparison of Obturation Removal Efficiency from Straight Root Canals with ProTaper Gold or Reciproc Blue: A Micro-Computed Tomography Study. *J Clin Med*. 18;9(4), 2020.
- [25] Bago, I, Plotino, G, Katić, M, Ročan, M, Batinić, M, Anić, I. Evaluation of filling material remnants after basic preparation, apical enlargement and final irrigation in retreatment of severely curved root canals in extracted teeth. *International Endodontic Journal*, 2020; 53, 962–973
- [26] Giansiracusa Rubini A, Plotino G, Al-Sudani D et al. A new device to test cutting efficiency of mechanical endodontic instruments. *Medical Science Monitor* 2014; 20, 374–8.
- [27] Akbulut MB, Akman M, Terlemez A, Magat G, Sener S, Shetty H. Efficacy of Twisted File Adaptive, Reciproc and ProTaper Universal Retreatment instruments for root-canal-filling removal: A cone-beam computed tomography study. *Dent Mater J*. 2016;35(1):126-31.

Received 22nd February 2020; Revised 12th March 2021; Accepted
15th March 2021; Published 1st April 2021
Academic Editor: Shahrina Ismail
USIM Press
Malaysian Journal of Science, Health & Technology
Vol. 7, No. 1 (2021), 6 pages
Copyright 2021 Fakulti of Science and Technology, Universiti Sains
Islam Malaysia.